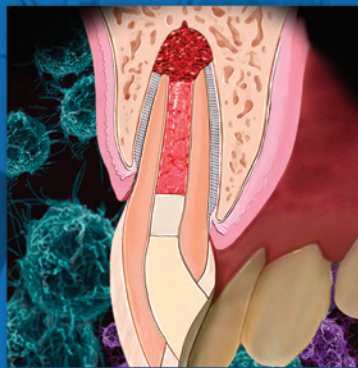


# ENDODONTICS



*Colleagues for  
Excellence*

Spring 2013

*Regenerative Endodontics*



Published for the Dental Professional Community by the  
***American Association of Endodontists.***

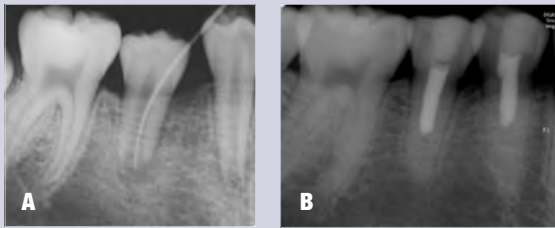
This issue sponsored by a grant from the ***AAE Foundation.***

[www.aae.org/colleagues](http://www.aae.org/colleagues)

## What is Regenerative Endodontics?

The management of immature permanent teeth with pulpal necrosis is challenging as the root canal system is often difficult to debride and the thin dentinal walls are at an increased risk of a subsequent cervical fracture (1). This results in a restorative problem since implants are generally contraindicated in young patients with a growing craniofacial skeleton. **Regenerative endodontic therapy** provides an alternative treatment approach that builds on the principles of regenerative medicine and tissue engineering. The aim of the therapy is to successfully treat these challenging cases by regenerating functional pulpal tissue utilizing protocols referred to as **regenerative endodontic procedures (REPs)**.

Regenerative endodontic therapy has been defined as “biologically based procedures designed to replace damaged structures, including dentin and root structures, as well as cells of the pulp-dentin complex” (2). In the immature tooth with pulpal necrosis, this optimally translates to complete restoration of pulpal function and subsequent completion of root development (3). Case studies have shown that healing of apical periodontitis, continued development of the root apex and increased thickness of the root canal wall of immature teeth with pulpal necrosis can occur after REPs (Figure 1).



**Fig. 1.** (A) Preoperative radiograph of tooth #29. (B) Five-year follow-up after regenerative endodontic treatment. Reprinted with permission from Jung IY, Lee SJ, Hargreaves KM. Biologically based treatment of immature permanent teeth with pulpal necrosis: a case series. J Endod 2008;34:876–87.

Regenerative endodontics evolved out of early experiments on the role of the blood clot in endodontic therapy (4), coupled with an understanding that revascularization, or reestablishment of a vascular supply to existing pulp tissue, is essential for continuation of root development after traumatic injuries (5). Other contributing factors have been the expansion of stem cell research, in particular the discovery of mesenchymal stem cells with the potential to differentiate into odontogenic-like cell lines (6, 7) and the potential for therapeutic applications of tissue engineering (8).

## What is Tissue Engineering?

Tissue engineering is an interdisciplinary field that integrates the principles of biology and engineering to develop biological substitutes that replace or regenerate human cells, tissue or organs in order to restore or establish normal function (9). There are three key elements for tissue engineering: **stem cells**, **scaffolds** and **growth factors**.

### Stem Cells

Stem cells are undifferentiated cells that continuously divide. There are two main types: embryonic, and adult or postnatal. Embryonic stem cells are capable of developing more than 200 cell types. In contrast, an adult stem cell can divide and create another cell like itself, and also a cell more differentiated than itself, but the capacity for differentiation into other cell types is limited. This is described as being “multipotent” and is a distinguishing feature of adult stem cells compared to the “pluripotent” or “omnipotent” properties seen in embryonic stem cells. Several types of adult stem cells have been isolated from teeth, as identified in the table above (9).

Dental Stem Cells	
DPSCs	Dental pulp stem cells (10)
SHEDs	Stem cells from human-exfoliated deciduous teeth (11)
PDLSCs	Periodontal ligament stem cells (12)
DFPCs	Dental follicle progenitor stem cells (13)
SCAPs	Stem cells from apical papilla (14, 15)

### Scaffolds

Scaffolds provide support for cell organization, proliferation, differentiation and vascularization (16). Current REPs have utilized dentin as well as the blood clot (17) or platelet-rich plasma (18) to provide scaffolds in the root canal. However, many types of biodegradable or permanent scaffolds made of natural (collagen, hyaluronic acid, chitosan and chitin) or synthetic (polylactic acid, polyglycolic acid, tricalcium phosphate, hydroxyapatite) materials are available (19, 20). Recently, peptide hydrogel nanofibers and various fibrin gels have been investigated as potential scaffolds for dental pulp tissue engineering (21).

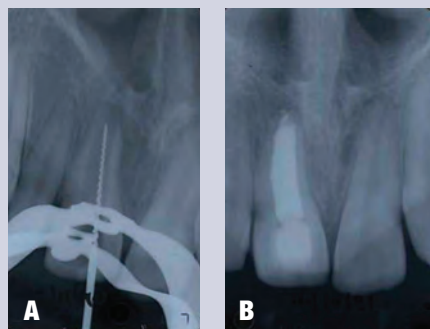
## Growth Factors

Growth factors are proteins that bind to receptors on the cell and act as signals to induce cellular proliferation and/or differentiation (2). Examples of key growth factors in pulp and dentin formation include bone morphogenetic protein (22), transforming growth factor- $\beta$  (23) and fibroblastic growth factor (24). Current REPs aim to utilize growth factors found in platelets (18) and dentin (25). Recent studies have shown that dentin contains a number of bioactive molecules that, when released, play an important role in regenerative procedures (25, 26).

## What is the Biological Basis for Regenerative Endodontic Therapy?

Historically, long-term calcium hydroxide treatment was used to induce apexification of the immature tooth with pulpal necrosis before placing an obturation material such as gutta-percha in the root canal system (27) (Figure 2). While the success rate of calcium hydroxide apexification is reported to be as high as 95%, there are several associated problems (28). These include:

1. The time required for formation of the calcified barrier (3-24 months) (27, 29)
2. Multiple appointments needed for reapplication of calcium hydroxide
3. The effect of long-term (several months or more) calcium hydroxide on the mechanical properties of dentin (30, 31)



**Fig. 2.** (A) Preoperative radiographic of tooth #8 prior to multi-appointment calcium hydroxide treatment to induce apexification. (B) One-year follow-up. While the tooth is asymptomatic and functional, thin root walls put the root at increased risk of fracture.

It has been proposed that exposure to calcium hydroxide denatures the carboxylate and phosphate groups in dentin (30). Other studies found the highest frequency of fracture occurred in teeth with the least developed roots (1).

Mineral trioxide aggregate (MTA), used as a root-end filling material, offers an alternative treatment for apexification. When placed adjacent to the periradicular tissues it induces the formation of cementum-like hard tissue and offers several advantages over calcium hydroxide apexification (32, 33). These include a reduction in treatment time and fewer patient visits, which in turn facilitate the timely restoration of the tooth. Studies on MTA apexification report that the success rate of the treatment is as high as 94% (34). Prospective clinical trials comparing MTA apexification to calcium hydroxide apexification report that the success rate of the former is comparable to or higher than that of the latter (35, 36). The long-term ( $\geq 2$  years) success rate of MTA apexification is yet to be evaluated.

However, neither of the apexification treatments fosters further root development and immature teeth remain vulnerable to cervical root fractures. In contrast, regenerative endodontic therapy has the potential for increased root development, and thus, may confer a better long-term prognosis. In addition, successful regeneration of the pulp-dentin complex would likely result in vital tissue capable of mounting an immune response and signaling tissue damage by sensory neurons.

## What are the Considerations for Clinical Regenerative Endodontic Procedures?

Various regenerative endodontic treatment protocols have been associated with a successful clinical outcome and currently there is no single recommended protocol. Common features of cases with successful clinical outcomes after REPs (3, 37) are:

1. Young patient
2. Necrotic pulp and immature apex
3. Minimal or no instrumentation of the dentinal walls
4. Placement of an intracanal medicament
5. Creation of a blood clot or protein scaffold in canal
6. Effective coronal seal



Regenerative endodontics often involves a two- or multi-step procedure (37, 38). The first appointment is centered on proper access and disinfection of the pulp space. Upon confirming the absence of clinical signs and symptoms, the second appointment focuses on removing the antimicrobial medicament, releasing growth factors from the dentin (e.g., by irrigating with ethylenediaminetetraacetic acid (EDTA)), delivering stem cells into the root canal by stimulating bleeding (39), creating a scaffold (e.g., blood clot or platelet-rich plasma) (17, 18), sealing the tooth by placing a pulp space barrier (e.g., MTA or resin-modified glass-ionomer) and permanent coronal restoration to prevent bacterial reinfection (40). At the second appointment, the use of local anesthetic without a vasoconstrictor may better facilitate stimulation of apical bleeding (41).

#### ADA CDT Codes for Pulpal Regeneration Procedures

##### First Phase of Treatment:

D3351 debridement and placement of antibacterial medication

##### Interim Phase (Repeat of First Phase):

D3352 interim medication replacement

##### Final Phase:

D3354 pulpal regeneration—(completion of regenerative treatment in an immature permanent tooth with a necrotic pulp); does not include final restoration

consensus on appropriate methods to evaluate clinical outcomes of regenerative endodontic therapies in humans where histological evaluation is not feasible.

As more evidence becomes available, modification of REPs is certain to evolve. For example, the triple antibiotic paste originally used by Banchs and Trope (17) has been shown in a recent *in vitro* study to be cytotoxic to stem cells at clinically recommended concentrations (42). As well, sodium hypochlorite and chlorhexidine can reduce the attachment of stem cells to dentin (43); in the case of NaOCl these effects have been shown to be reversed by EDTA (44).

Before commencing regenerative endodontic treatment it is imperative that patients and legal guardians are informed that two or more appointments may be needed and that follow-up appointments are essential in order to evaluate the clinical outcomes (Figure 3). Pain, soft tissue swelling or increasing radiolucency indicates failure of the procedure and an alternative treatment (artificial apical barrier with MTA or extraction) would be recommended.

#### Guidelines for Follow-up Evaluation

- **Tooth is asymptomatic and functional**
- **Radiographic evaluation:**
  - 6-12 months*
    - \* Resolution of periapical radiolucency
    - \* May see increased dentinal wall thickness
  - 12-24 months*
    - \* Increased dentinal wall thickness
    - \* Increased root length

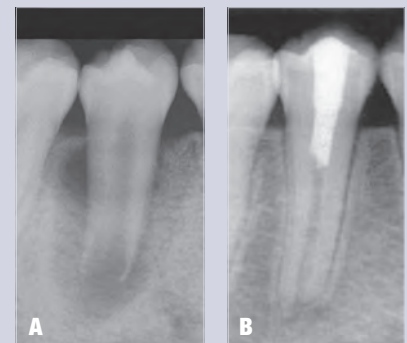
**Fig. 3.** Guidelines for clinical and radiographic follow-up evaluation after regenerative endodontic procedures

proliferation and differentiation, and a bacterial tight seal of the access opening (46). This new treatment approach was proposed as a conservative alternative for young permanent teeth with immature roots and pulpal necrosis (17, 47).

The majority of human case studies have shown good clinical outcomes (absence of clinical signs and symptoms, radiographic evidence of resolution of periapical infections, continued root development and increased canal wall thickness) for immature

#### What are the Outcomes of Regenerative Endodontic Procedures?

Successful clinical outcomes following revascularization procedures for immature permanent mandibular premolar teeth with pulpal necrosis and periapical infection were reported in landmark case reports by Iwahu et al (45) and Banchs and Trope (17) (Figure 4). Three important treatment factors were identified—disinfection of the root canal, placement of a matrix in the canal conducive to cellular



**Fig. 4.** (A) Preoperative radiograph of tooth #29. (B) 24-month follow-up after regenerative endodontic treatment. Reprinted with permission from Banchs F, Trope M. Revascularization of immature permanent teeth with apical periodontitis: new treatment protocol? J Endod 2004;30:196-200.

permanent teeth with pulpal necrosis following REPs (37, 38, 48). Additional studies can be reviewed in the exclusive online bonus material for this newsletter, available at [www.aae.org/colleagues](http://www.aae.org/colleagues). A recent retrospective analysis of radiographic and survival outcomes of 61 immature teeth treated with either REPs or apexification found significantly greater increases in root length and thickness following REPs in comparison with either calcium hydroxide apexification or MTA apexification (49).

For obvious reasons there is limited information on the exact histological nature of the tissue in the root canal following REPs in humans. However, two recent reports describe the presence of pulp-like tissue in human teeth extracted following REPs (50, 51). In dogs, deposition of cementum- and bone-like tissues was observed after REPs (52, 53), suggesting differentiation of periodontal ligament tissue versus pulp tissue.

Based on case studies, the healing progression following REPs will vary depending on the initial presentation. A positive response to cold and/or electric pulp tests occurs in some cases (37). Radiographic evidence of apical healing typically precedes continuation of root development. Figure 5 shows a mandibular second premolar 18 months after REPs that remains asymptomatic and functional with complete periapical healing and apical closure, but minimal increase in root length, an outcome that should be considered acceptable (37).

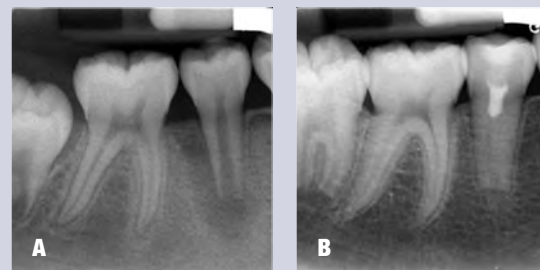


Fig. 5. (A) Preoperative radiograph of tooth #29. B. 18-month review following regenerative endodontic treatment. Courtesy of Dr. Paul Brent, Portland, Ore.

### What Could Regenerative Endodontics Look Like in the Future?

Current regenerative endodontic protocols rely on:

1. Irrigants to disinfect the canal and release growth factors found in dentin
2. Bleeding from the periapical area to bring cells and growth factors into the root canal
3. The blood clot and dentin walls to provide scaffolds for the generation of new tissue (17, 25, 54) (Figure 6)

It is clear that the many possible clinical variables do not give the clinician control of the stem cell/growth factors/scaffold composition. In the future, the challenge of generating tissues that mimic the original pulp and dentin-like structure might be more effectively addressed by using tissue engineering approaches under more controlled clinical conditions (54, 55). Such approaches might rely more on therapies that utilize autologous stem cells combined with customized scaffolds and delivery of appropriate growth factors at the right time and in the right sequence. Further translational research is needed to learn about these processes and, importantly, ensure that new protocols are clinically practical (56).

It is evident that recent rapid advances have opened the door to exciting new opportunities in the quest for healing immature teeth with pulpal necrosis. Extension of these advances to the treatment of mature teeth with pulpal necrosis would provide significant therapeutic benefits by enabling retention of the natural dentition in a larger patient pool. Recent reports describing the presence of mesenchymal stem/progenitor cells with regenerative capabilities in human inflamed pulps (57) and inflamed periapical tissue (58) present intriguing possibilities yet to be explored for the treatment of the mature tooth with pulpal necrosis and apical periodontitis. Clearly, while current protocols have undergone rapid evolution to improve outcomes, it is likely that future REPs will differ from current practice and have the potential to provide benefits for a larger proportion of the population.

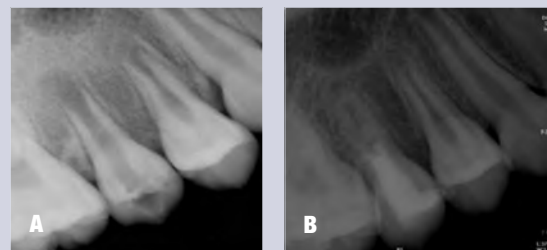

Fig. 6. (A) Preoperative radiograph of tooth #4. (B) 5-year follow-up after regenerative endodontic treatment. Reprinted with permission from Jung IY, Lee SJ, Hargreaves KM. Biologically based treatment of immature permanent teeth with pulpal necrosis: a case series. J Endo 2008;34:876–87.

### Summary

Regenerative endodontics is one of the most exciting developments in dentistry today and endodontists are at the forefront of this cutting-edge research. Endodontists' knowledge in the fields of pulp biology, dental trauma and tissue engineering can be applied to deliver biologically based regenerative endodontic treatment of necrotic immature permanent teeth resulting in continued root development, increased thickness in the dentinal walls and apical closure. These developments in regeneration of a functional pulp-dentin complex have a promising impact on efforts to retain the natural dentition, the ultimate goal of endodontic treatment.

## References

1. Cvek M. Prognosis of luxated non-vital maxillary incisors treated with calcium hydroxide and filled with gutta-percha. A retrospective clinical study. *Endod Dent Traumatol* 1992;8:45-55.
2. Murray PE, Garcia-Godoy F, Hargreaves KM. Regenerative endodontics: a review of current status and a call for action. *J Endod* 2007;33:377-90.
3. Hargreaves KM, Giesler T, Henry M, et al. Regeneration potential of the young permanent tooth: what does the future hold? *J Endod* 2008;34:S51-6.
4. Nygaard-Östby B. The role of the blood clot in endodontic therapy. An experimental histologic study. *Acta Odontol Scand* 1961;19:324-53.
5. Andreasen JO, Andreasen FM. Textbook and color atlas of traumatic injuries to the teeth. 3<sup>rd</sup> ed. Munksgaard, St Louis, MO; 1994.
6. Caplan AI. Mesenchymal stem cells. *J Orthop Res* 1991;9:641-50.
7. Huang GT, Gronthos S, Shi S. Mesenchymal stem cells derived from dental tissues vs. those from other sources: their biology and role in regenerative medicine. *J Dent Res* 2009;88:792-806.
8. Langer R, Vacanti JP. Tissue engineering. *Science* 1993;260:920-6.
9. Sedgley CM, Botero TM. Dental stem cells and their sources. *Dent Clin North Am* 2012;56:549-61.
10. Gronthos S, Mankani M, Brahimi J, et al. Postnatal human dental pulp stem cells (DPSCs) *in vitro* and *in vivo*. *Proc Natl Acad Sci USA* 2000;97:13625-30.
11. Miura M, Gronthos S, Zhao M, et al. SHED: stem cells from human exfoliated deciduous teeth. *Proc Natl Acad Sci USA* 2003;100:5807-12.
12. Seo BM, Miura M, Sonoyama W, et al. Recovery of stem cells from cryopreserved periodontal ligament. *J Dent Res* 2005;84:907-12.
13. Morsczeck C, Gotz W, Schierholz J, et al. Isolation of precursor cells (PCs) from human dental follicle of wisdom teeth. *Matrix Biol* 2005;24:155-65.
14. Huang GT, Sonoyama W, Liu Y, et al. The hidden treasure in apical papilla: the potential role in pulp/dentin regeneration and bioroot engineering. *J Endod* 2008;34:645-51.
15. Sonoyama W, Liu Y, Yamaza T, et al. Characterization of the apical papilla and its residing stem cells from human immature permanent teeth: a pilot study. *J Endod* 2008;34:166-71.
16. Bohl KS, Shon J, Rutherford B, et al. Role of synthetic extracellular matrix in development of engineered dental pulp. *J Biomater Sci Polym Ed* 1998;9:749-64.
17. Banchs F, Trope M. Revascularization of immature permanent teeth with apical periodontitis: new treatment protocol? *J Endod* 2004;30:196-200.
18. Torabinejad M, Turman M. Revitalization of tooth with necrotic pulp and open apex by using platelet-rich plasma: a case report. *J Endod* 2011;37:265-8.
19. Gotlieb EL, Murray PE, Namerow KN, et al. An ultrastructural investigation of tissue-engineered pulp constructs implanted within endodontically treated teeth. *J Am Dent Assoc* 2008;139:457-65.
20. Chandrasekhar S, Murray PE, Namerow KN. Proliferation of mature *ex vivo* human dental pulp using tissue engineering scaffolds. *J Endod* 2011;37:1236-9.
21. Galler KM, Hartgerink JD, Cavender AC, et al. A customized self-assembling peptide hydrogel for dental pulp tissue engineering. *Tissue Eng Part A* 2012;18:176-84.
22. Nakashima M. Bone morphogenetic proteins in dentin regeneration for potential use in endodontic therapy. *Cytokine Growth Factor Rev* 2005;16:369-76.
23. Chan CP, Lan WH, Chang MC, et al. Effects of TGF-beta<sub>1</sub> on the growth, collagen synthesis and collagen lattice contraction of human dental pulp fibroblasts *in vitro*. *Arch Oral Biol* 2005;50:469-79.
24. Ishimatsu H, Kitamura C, Morotomi T, et al. Formation of dentinal bridge on surface of regenerated dental pulp in dentin defects by controlled release of fibroblast growth factor-2 from gelatin hydrogels. *J Endod* 2009;35:858-65.
25. Smith AJ, Scheven BA, Takahashi Y, et al. Dentine as a bioactive extracellular matrix. *Arch Oral Biol* 2012;57:109-21.
26. Sun HH, Jin T, Yu Q, et al. Biological approaches toward dental pulp regeneration by tissue engineering. *J Tissue Eng Regen Med* 2011;5:e1-16.
27. Frank AL. Therapy for the divergent pulpless tooth by continued apical formation. *J Am Dent Assoc* 1966;72:87-93.
28. Kerkis I, Kerkis A, Dozortsev D, et al. Isolation and characterization of a population of immature dental pulp stem cells expressing OCT-4 and other embryonic stem cell markers. *Cells Tissues Organs* 2006;184:105-16.
29. Webber RT. Apexogenesis versus apexification. *Dent Clin North Am* 1984;28:669-97.
30. Andreasen JO, Farik B, Munksgaard EC. Long-term calcium hydroxide as a root canal dressing may increase risk of root fracture. *Dent Traumatol* 2002;18:134-7.
31. Rosenberg B, Murray PE, Namerow K. The effect of calcium hydroxide root filling on dentin fracture strength. *Dent Traumatol* 2007;23:26-9.
32. Torabinejad M, Hong CU, Lee SJ, et al. Investigation of mineral trioxide aggregate for root-end filling in dogs. *J Endod* 1995;21:603-8.

33. Shabahang S, Torabinejad M, Boyne PP, et al. A comparative study of root-end induction using osteogenic protein-1, calcium hydroxide, and mineral trioxide aggregate in dogs. *J Endod* 1999;25:1-5.
34. Sarris S, Tahmassebi JF, Duggal MS, et al. A clinical evaluation of mineral trioxide aggregate for root-end closure of non-vital immature permanent incisors in children-a pilot study. *Dent Traumatol* 2008;24:79-85.
35. El-Meligy OA, Avery DR. Comparison of apexification with mineral trioxide aggregate and calcium hydroxide. *Pediatr Dent* 2006;28:248-53.
36. Pradhan DP, Chawla HS, Gauba K, et al. Comparative evaluation of endodontic management of teeth with unformed apices with mineral trioxide aggregate and calcium hydroxide. *J Dent Child (Chic)* 2006;73:79-85.
37. Law A. Considerations for regeneration procedures. *J Endod* 2013;39(3 Suppl):S44-56.
38. Geisler TM. Clinical considerations for regenerative endodontic procedures. *Dent Clin North Am* 2012;56:603-26.
39. Lovelace TW, Henry MA, Hargreaves KM, et al. Evaluation of the delivery of mesenchymal stem cells into the root canal space of necrotic immature teeth after clinical regenerative endodontic procedure. *J Endod* 2011;37:133-8.
40. Jung IY, Lee SJ, Hargreaves KM. Biologically based treatment of immature permanent teeth with pulpal necrosis: a case series. *J Endod* 2008;34:876-87.
41. Petrino JA, Boda KK, Shambarger S, et al. Challenges in regenerative endodontics: a case series. *J Endod* 2010;36:536-41.
42. Ruparel NB, Teixeira FB, Ferraz CC, et al. Direct effect of intracanal medicaments on survival of stem cells of the apical papilla. *J Endod* 2012;38:1372-5.
43. Ring KC, Murray PE, Namerow KN, et al. The comparison of the effect of endodontic irrigation on cell adherence to root canal dentin. *J Endod* 2008;34:1474-9.
44. Galler KM, D'Souza RN, Federlin M, et al. Dentin conditioning codetermines cell fate in regenerative endodontics. *J Endod* 2011;37:1536-41.
45. Iwaya SI, Ikawa M, Kubota M. Revascularization of an immature permanent tooth with apical periodontitis and sinus tract. *Dent Traumatol* 2001;17:185-7.
46. Windley III W, Teixeira F, Levin L, et al. Disinfection of immature teeth with a triple antibiotic paste. *J Endod* 2005;31:439-43.
47. Trope M. Treatment of the immature tooth with a non-vital pulp and apical periodontitis. *Dent Clin North Am* 2010;54:313-24.
48. Hargreaves KM, Diogenes A, Teixeira F. Treatment options: biological basis of regenerative endodontic procedures. *J Endod* 2013;39(3 Suppl):S30-43.
49. Jeeruphan T, Jantarat J, Yanpiset K, et al. Mahidol study 1: comparison of radiographic and survival outcomes of immature teeth treated with either regenerative endodontic or apexification methods: a retrospective study. *J Endod* 2012;38:1330-6.
50. Torabinejad M, Faras H. A clinical and histological report of a tooth with an open apex treated with regenerative endodontics using platelet-rich plasma. *J Endod* 2012;38:864-8.
51. Shimizu E, Jong G, Partridge N, et al. Histologic observation of a human immature permanent tooth with irreversible pulpitis after revascularization/regeneration procedure. *J Endod* 2012;38:1293-7.
52. Thibodeau B, Teixeira F, Yamauchi M, et al. Pulp revascularization of immature dog teeth with apical periodontitis. *J Endod* 2007;33:680-9.
53. Wang X, Thibodeau B, Trope M, et al. Histologic characterization of regenerated tissues in canal space after the revitalization/revascularization procedure of immature dog teeth with apical periodontitis. *J Endod* 2010;36:56-63.
54. Galler KM, D'Souza RN. Tissue engineering approaches for regenerative dentistry. *Regen Med* 2011;6:111-24.
55. Smith AJ, Lesot H. Induction and regulation of crown dentinogenesis: embryonic events as a template for dental tissue repair? *Crit Rev Oral Biol Med* 2001;12:425-37.
56. Goodis HE, Kinaia BM, Kinaia AM, et al. Regenerative endodontics and tissue engineering: what the future holds? *Dent Clin North Am* 2012;56:677-89.
57. Alongi DJ, Yamaza T, Song Y, et al. Stem/progenitor cells from inflamed human dental pulp retain tissue regeneration potential. *Regen Med* 2010;5:617-31.
58. Liao J, Al Shahrani M, Al-Habib M, et al. Cells isolated from inflamed periapical tissue express mesenchymal stem cell markers and are highly osteogenic. *J Endod* 2011;37:1217-24.





***This issue of Colleagues is supported by a grant from the AAE Foundation.***

The Foundation shares the Association's goal of establishing endodontists as the leaders in regenerative dentistry and has made a multi-million dollar commitment to support research in regeneration.

The AAE Foundation fosters excellence in endodontic research, education and patient care. It is the only organization that supports every accredited endodontic program in the United States and Canada. The Foundation invests more than \$1 million annually to advance this mission. Every dollar impacts:

- *A resident's training*
- *An educator's development*
- *An endodontic department's success*
- *The specialty's future*
- *A patient's quality of care*

For more information about the Foundation's grants and research visit [www.aae.org/foundation](http://www.aae.org/foundation).

The Foundation would like your feedback about this issue of *Colleagues*. Please visit [www.aae.org/foundation/news](http://www.aae.org/foundation/news) to take a short survey.

The AAE wishes to thank the members of its Regenerative Endodontics Committee for authoring this issue of the newsletter: Drs. Christine M. Sedgley, Pavel Cherkas, Sami M.A. Chogle, Todd M. Geisler, Kenneth M. Hargreaves, Avina K. Paranjpe and Valerie Tom-Kun Yamagishi. Thanks also to the following article reviewers: Drs. Steven J. Katz, James C. Kulild, Robert S. Roda, James F. Wolcott and Susan L. Wolcott.



**Exclusive Online Bonus Materials: Regenerative Endodontics**

This issue of the *Colleagues* newsletter is available online at [www.aae.org/colleagues](http://www.aae.org/colleagues) with the following *exclusive bonus materials*:

- Regenerative Endodontics Case Studies Listing
- Considerations for Regenerative Procedures

**Earn CE Online With *Colleagues***

With an annual subscription to the **AAE Live Learning Center**, you can earn CE credit online for the *ENDODONTICS: Colleagues for Excellence* newsletter series and much more. Visit [www.aae.org/livelearningcenter](http://www.aae.org/livelearningcenter) today.

*The information in this newsletter is designed to aid dentists. Practitioners must use their best professional judgment, taking into account the needs of each individual patient when making diagnosis/treatment plans. The AAE neither expressly nor implicitly warrants against any negative results associated with the application of this information. If you would like more information, consult your endodontic colleague or contact the AAE.*

*Did you enjoy this issue of Colleagues? Are there topics you would like to cover in the future? We want to hear from you! Send your comments and questions to the American Association of Endodontists at the address below, and visit the Colleagues online archive at [www.aae.org/colleagues](http://www.aae.org/colleagues) for back issues of the newsletter.*



©2013, American Association of Endodontists  
211 E. Chicago Ave., Suite 1100  
Chicago, IL 60611-2691

Phone: 800/872-3636 (U.S., Canada, Mexico) or 312/266-7255  
Fax: 866/451-9020 (U.S., Canada, Mexico) or 312/266-9867  
Email: [info@aae.org](mailto:info@aae.org) Website: [www.aae.org](http://www.aae.org)



[www.facebook.com/endodontists](http://www.facebook.com/endodontists)

[@aaenews](https://twitter.com/aaenews) / [@savingyourteeth](https://twitter.com/savingyourteeth)

[www.youtube.com/rootcanalspecialists](http://www.youtube.com/rootcanalspecialists)